

PATIENT

Bella Goyer

SPECIES

Canine

BREED

Westie

SEX

FS

AGE

10 years

WEIGHT

22 #

INTERPRETED BY

Remo Lobetti, BVSc,
MMedVet (Med), PhD,
Dipl. ECVIM

IMAGING PERFORMED BY

Lara Wiseman, DVM

HOSPITAL NAME

Boca Midtowne Animal
Hospital

REFERRING VET

Dr Boazman

INVOICE

302757

DATE

2/16/22

PRESENTING CLINICAL SIGNS

History: Stage B2 heart disease, recent episode of respiratory distress (resolved) and polydipsia.

Physical Examination: Hypertensive (210).

Urinalysis: N/A.

CBC: Pending.

Serum Biochemistry: Pending.

Radiographic Findings: Left atrial enlargement, hepatomegaly, IVDD, broncho-interstitial lung pattern.

ULTRASONOGRAPHIC EXAMINATION OF THE ABDOMEN

Urinary System

Full urinary bladder with a normal appearance and thickness of the wall. Normal anechoic urine with no sediment or uroliths evident.

Normal trigone area, proximal urethra (0.41 cm), and iliac blood vessels.

Normal iliac lymph nodes. Ureters not visualized.

Normal renal size (left 4.5 cm, right 4.4 cm) with increased echogenic appearance, some loss of cortico-medullary differentiation, and normal capsule and pelvis.

Reproductive System

N/A.

Adrenal Glands

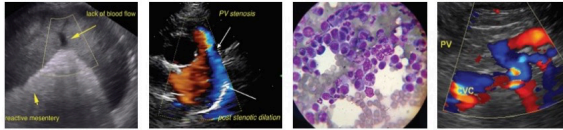
Normal shape, echogenic appearance, size, and position. Left 0.41 cm, right 0.45 cm.

Spleen

Normal size (1 cm) and echogenic appearance. Smooth homogenous parenchyma, smooth curvi-linear capsule, and normal vasculature. No evidence of inflammatory, neoplastic, infarction, or infiltrative changes noted. Incidental myelolipoma

Liver

Enlarged with a diffuse increased echogenic appearance, and loss of portal markings. No nodules or masses evident. Full gall bladder containing normal anechoic bile. Normal thickness and appearance of the gall bladder wall. Normal bile duct.



PATIENT

Bella Goyer

SPECIES

Canine

BREED

Westie

SEX

FS

AGE

10 years

WEIGHT

22 #

INTERPRETED BY

Remo Lobetti, BVSc,
MMedVet (Med), PhD,
Dipl. ECVIM

IMAGING PERFORMED BY

Lara Wiseman, DVM

HOSPITAL NAME

Boca Midtowne Animal
Hospital

REFERRING VET

Dr Boazman

INVOICE

302757

DATE

2/16/22

Gastrointestinal

Normal appearance of the stomach, duodenum, small intestine, ileo-cecal junction, and colon with no loss of layering, normal wall thickness (stomach 0.34 cm, duodenum 0.34 cm, jejunum 0.33 cm) and peristalsis, and no distension of the lumen.

Pancreas

Normal size (right 1 cm) and echogenic appearance. Regular capsule. Normal echogenic appearance of the mesentery and fat surrounding the pancreas.

Free Abdomen

No mesenteric lymphadenomegaly.
No ascites.

ULTRASONOGRAPHIC FINDINGS

Primary findings:

- Hepatopathy.

Secondary findings:

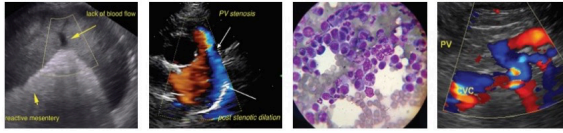
- Age-related renal changes.

INTERPRETATION OF THE FINDINGS & FURTHER RECOMMENDATIONS

Etiologies for the hepatopathy would be secondary to the cardiac disease, reactive, hyperplasia, vacuolar, metabolic, chronic hepatitis, and infiltrative neoplasia.

Further assessment needs to be based on the pending blood work but could include FNA cytology of the liver.

Specific therapy would be dependent on an etiological diagnosis.



PATIENT

Bella Goyer

IMAGES

Liver

SPECIES

Canine

BREED

Westie

SEX

FS

AGE

10 years

WEIGHT

22 #

INTERPRETED BY

Remo Lobetti, BVSc,
MMedVet (Med), PhD,
Dipl. ECVIM

IMAGING PERFORMED BY

Lara Wiseman, DVM

HOSPITAL NAME

Boca Midtowne Animal
Hospital

REFERRING VET

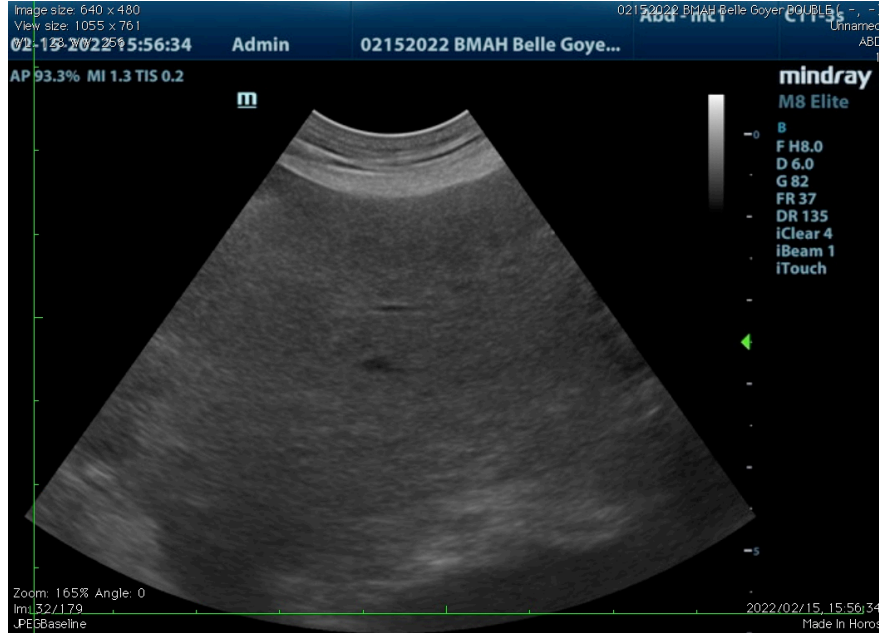
Dr Boazman

INVOICE

302757

DATE

2/16/22



The information and recommendations provided are based on the images presented by the referring veterinarian. No evaluation can be communicated regarding pathology that was not visible in the image/video clips provided.

Thank you for this referral. If the clinical or image interpretation does not parallel your findings or if I can be of any further assistance please contact me.

Remo Lobetti, BVSc, MMedVet (Med), PhD, Dipl. ECVIM (Internal Medicine)
rlobetti@mweb.co.za